

M Bret Blackford

DOB: 7/16/64 (59yrs)

Sex: Male

EKG Recording Overview

Kardia Advanced Determination:

Normal Sinus Rhythm

*Kardia Advanced Determination is done on Lead I.

Recorded on:	Monday, October 23, 2023 at 6:01:16 AM
Heart Rate:	63 BPM
Duration:	30s

Additional Information

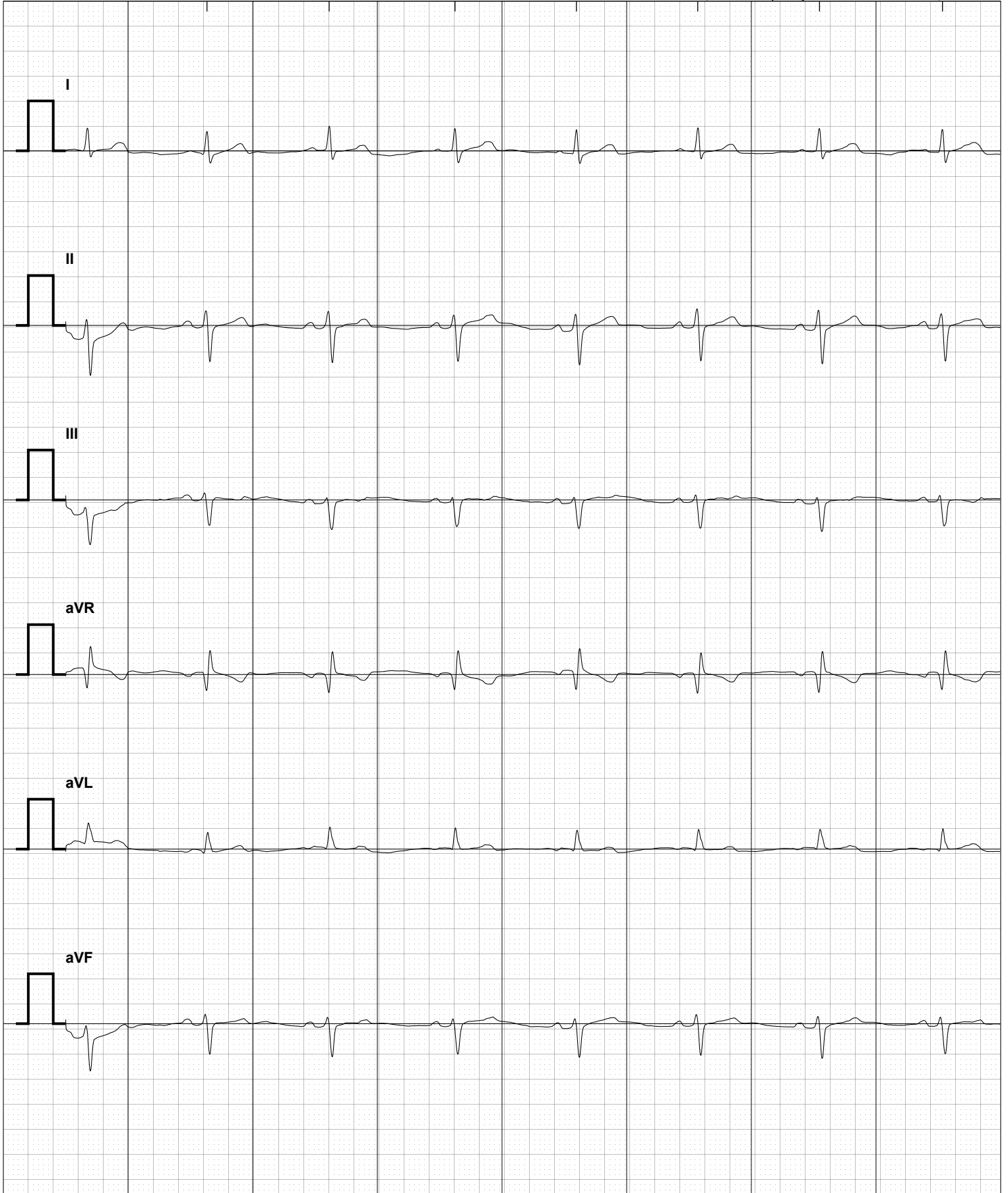
No additional information to display

Kardia does not check for heart attack. If you believe you are having a medical emergency, call emergency services. AliveCor does not provide medical advice or services, and any information from AliveCor is provided to assist you and your doctor with your medical care and not as a replacement for consulting with your doctor.

Patient: M Bret Blackford
Recorded: Monday, October 23, 2023 at 6:01:16 AM
Heart Rate: 63 BPM
Duration: 30s

Kardia Advanced Normal Sinus Rhythm
Determination:
*Kardia Advanced Determination is done on Lead I.

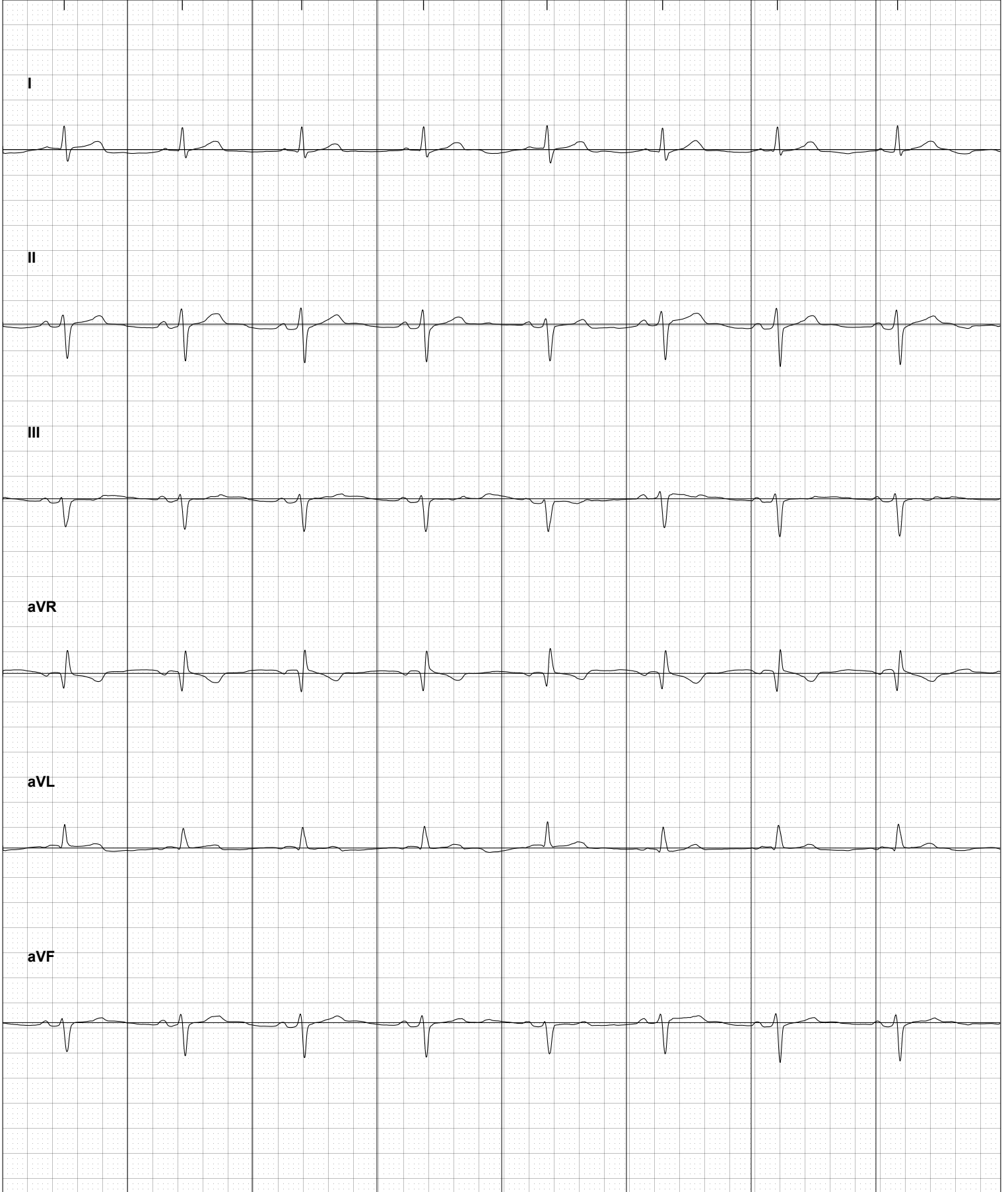
Enhanced Filter, Mains Frequency: 60Hz Scale: 25mm/s, 10mm/mV



Patient: M Bret Blackford
Recorded: Monday, October 23, 2023 at 6:01:16 AM
Heart Rate: 63 BPM
Duration: 30s

Kardia Advanced Normal Sinus Rhythm
Determination:
*Kardia Advanced Determination is done on Lead I.

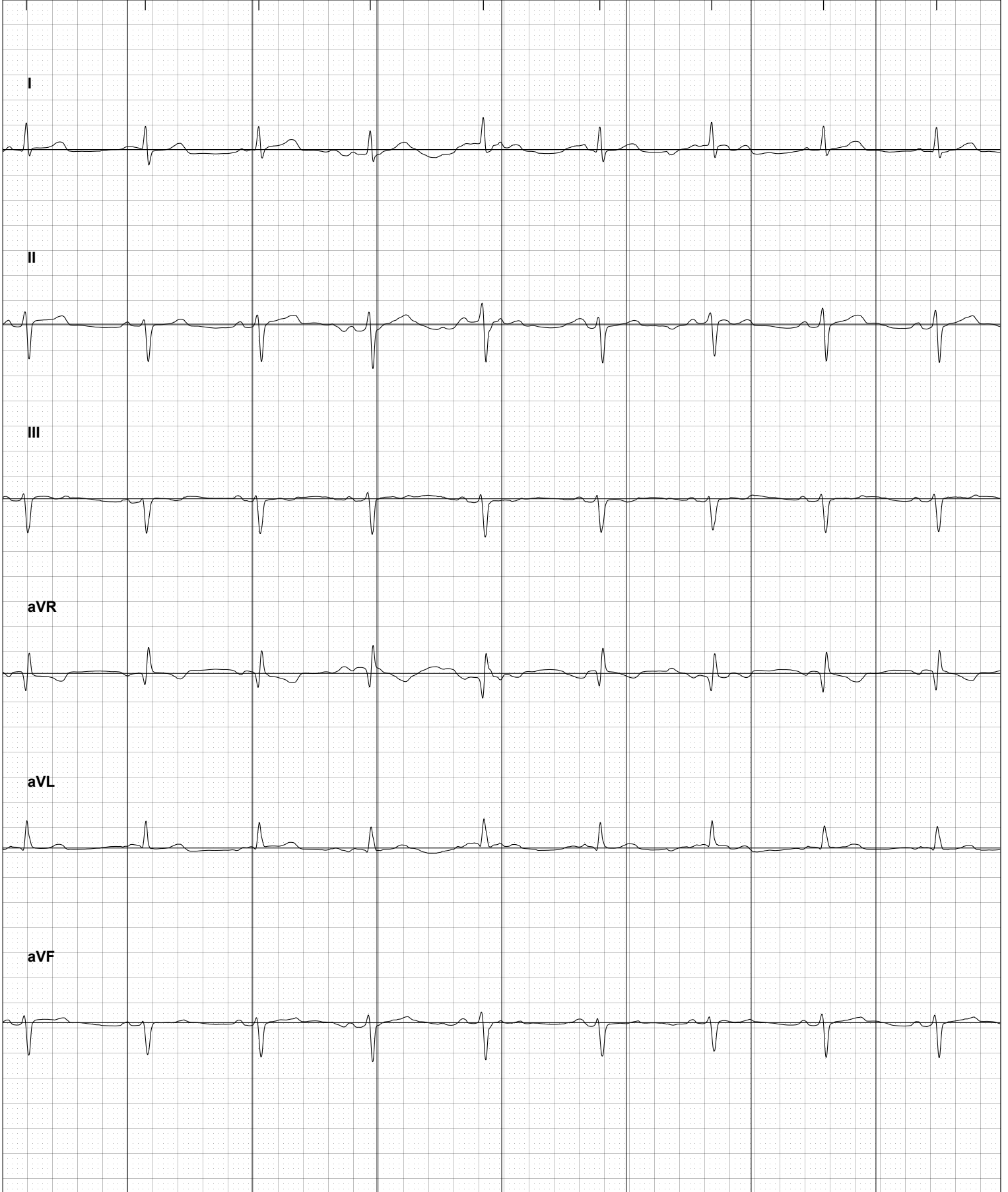
Enhanced Filter, Mains Frequency: 60Hz Scale: 25mm/s, 10mm/mV



Patient: M Bret Blackford
Recorded: Monday, October 23, 2023 at 6:01:16 AM
Heart Rate: 63 BPM
Duration: 30s

Kardia Advanced Normal Sinus Rhythm
Determination:
*Kardia Advanced Determination is done on Lead I.

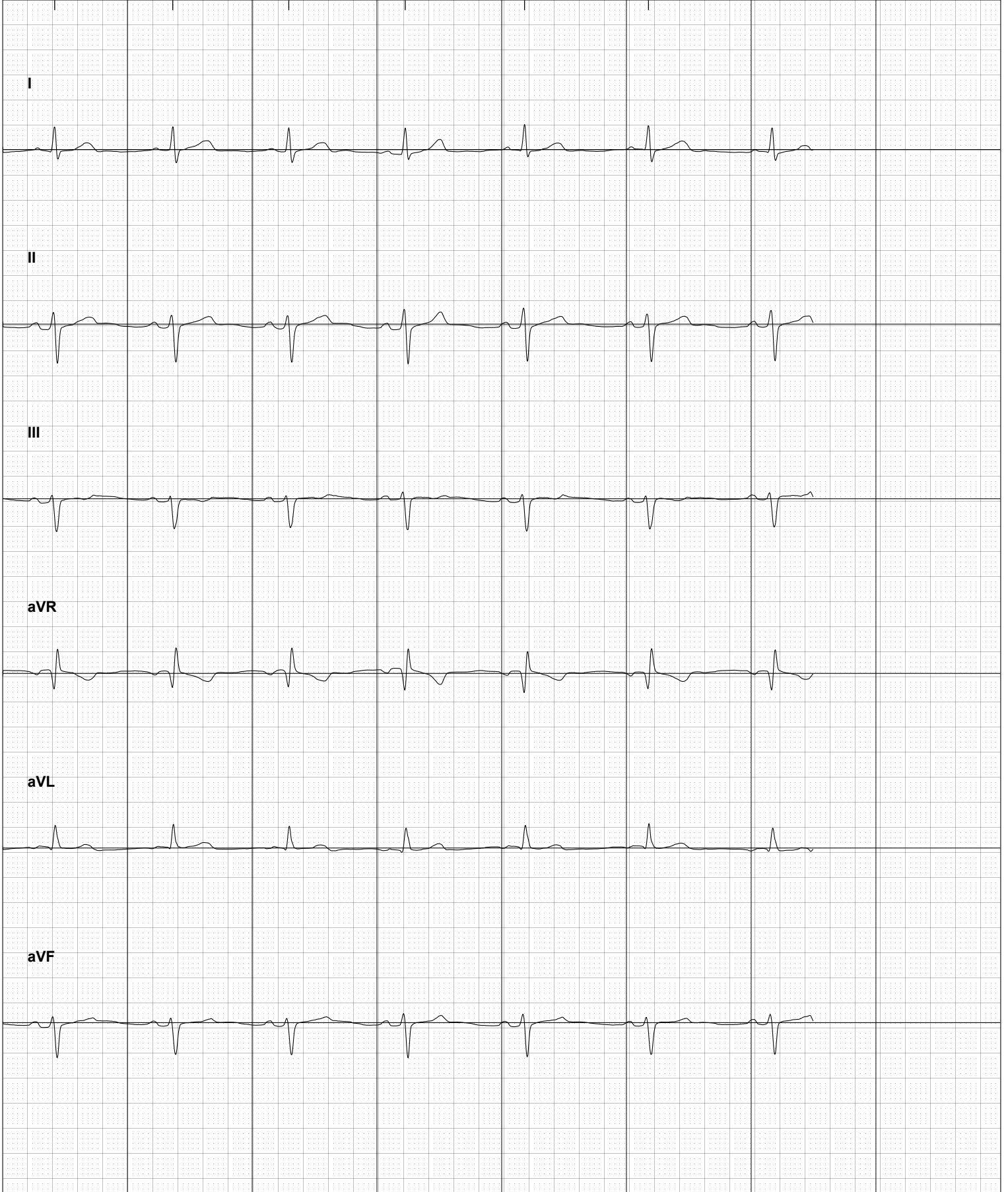
Enhanced Filter, Mains Frequency: 60Hz Scale: 25mm/s, 10mm/mV



Patient: M Bret Blackford
Recorded: Monday, October 23, 2023 at 6:01:16 AM
Heart Rate: 63 BPM
Duration: 30s

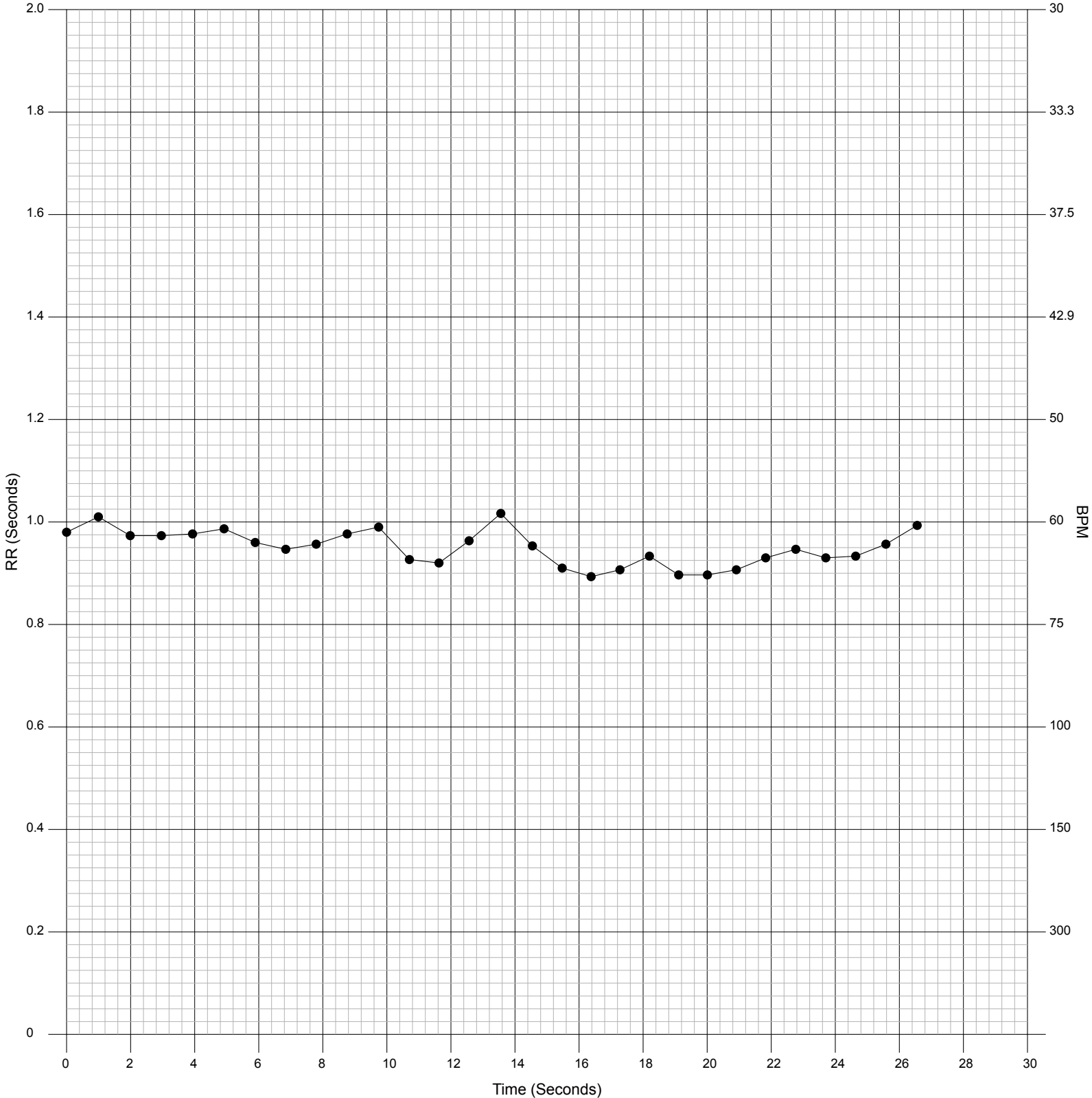
Kardia Advanced Normal Sinus Rhythm
Determination:
*Kardia Advanced Determination is done on Lead I.

Enhanced Filter, Mains Frequency: 60Hz Scale: 25mm/s, 10mm/mV



R-R Interval Plot

Detection of QRS locations allows Kardia AI to measure the distance between heartbeats or the RR interval. This can be used to review variability of heart rate, which may be useful in understanding heart rate variability, or to visually display irregularity in rate (such as in Afib).



Average Beat Plot

The average beat display is the average of all the normal, non-ectopic (extra/missed) beats in the ECG. An average beat display is intended to be a simple visual representation of one beat in a 30-second ECG.

